

Bilateral Post-Traumatic Skull Defect

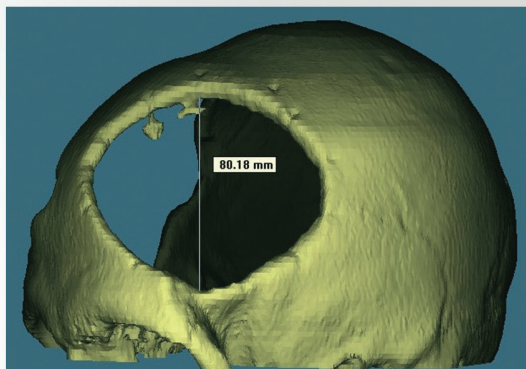


Fig. 1

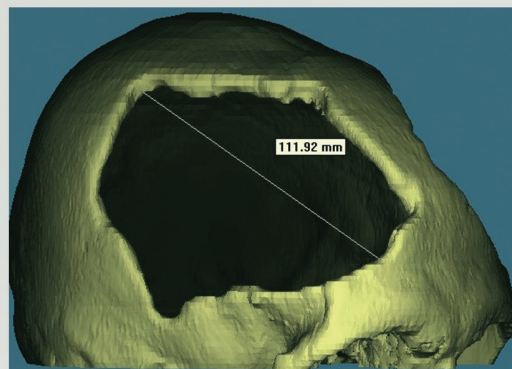


Fig. 2

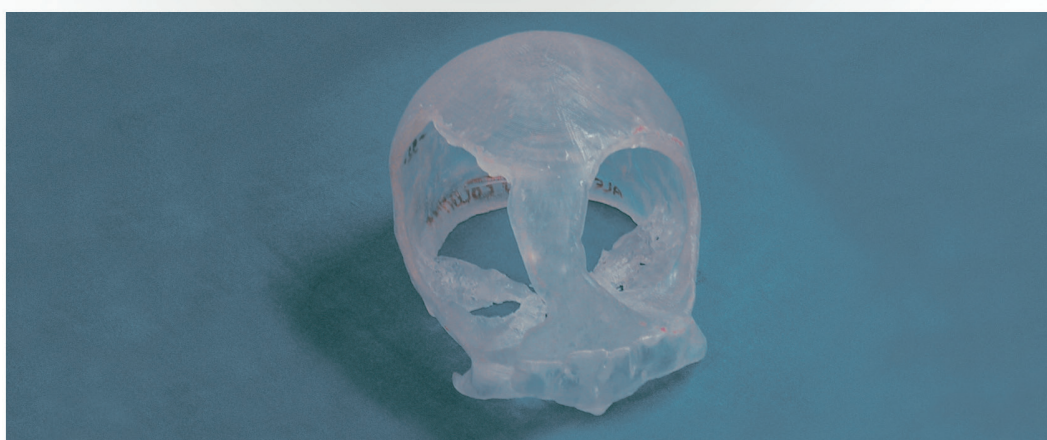

Fig. 3

CustomBone Service

Male 20-years old: The patient had multiple injuries following a car accident and was in a deep coma on his arrival to the Emergency Room (GCS 5/15). A CT scan of the brain showed a large left extradural haematoma associated with a serious cerebral oedema. Therefore, urgent neurosurgery was performed with left frontal craniotomy, evacuation of the haematoma and osteo-dural decompression. A brain CT scan follow-up, performed approximately 20 hours later, confirmed the still-present oedema and the onset of a new right frontal extradural haematoma. A new right frontal craniotomy operation was performed with evacuation of the haematoma and osteo-dural decompression. Following this operation, the patient's neurological conditions underwent a moderate but gradual improvement. About two months after the trauma, exophthalmos and conjunctival chemosis set in.

An angiographic study confirmed the presence of a post-traumatic carotid-cavernous fistula, which was treated endovascularly.

The patient then continued rehabilitation treatment and was considered suitable for a CustomBone implant. Based on 3D CT scans (Fig. 1 and 2), a stereolithographic model of the patient's skull was produced (Fig. 3) and two custom-made porous hydroxyapatite devices were made to fill the bilateral skull defects.

Bilateral Post-Traumatic Skull Defect

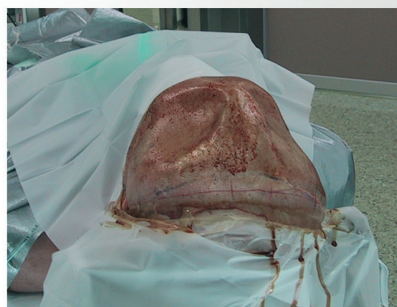

Fig. 4

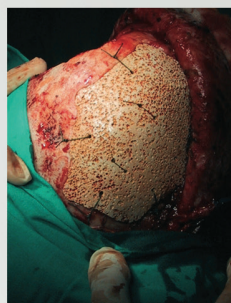


Fig. 5

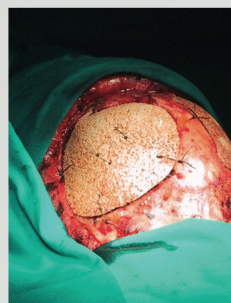


Fig. 6

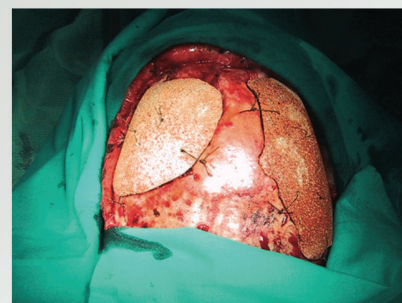


Fig. 7

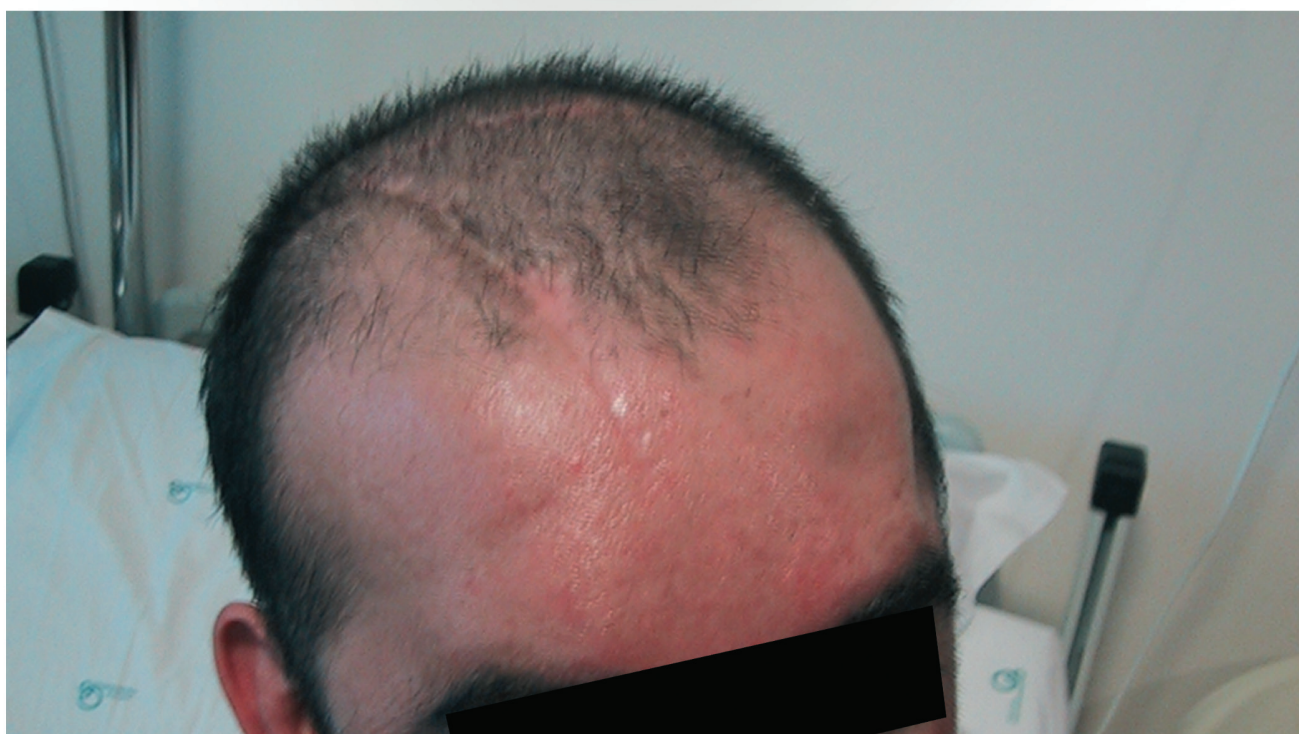

Fig. 8

Approximately 10 months after the trauma, surgery was performed to implant the two devices during a single surgical procedure (Fig. 4-7). A CT scan was immediately performed,

which evidenced the correctly placed implants. Two months following the implantation, a clear clinical improvement was observed as well as a good aesthetical outcome (Fig. 8).