

Repair of a Partially Transected Median Nerve with Avance® Nerve Graft: A Processed Nerve Allograft

Scott M. Wisotsky, MD, Orthopaedic Associates of West Florida, Clearwater, FL

Introduction

Peripheral nerve injuries affect hundreds of thousands of patients every year in the United States alone. Patients with peripheral nerve trauma are frequently at the peak of their employment productivity and thus any ensuing loss of function is particularly devastating. Surgeons may choose to directly repair these nerve deficits, however excess tension in a direct repair can lead to impaired axonal growth or neuroma formation.¹ In order to perform a tensionless repair, surgeons look for solutions that give more reliable outcomes, provide a variety of sizes, are easy to use and bring vascularity to the repair site.

As an off-the-shelf option, Avance® Nerve Graft is a decellularized and cleansed extracellular matrix processed from donated human peripheral nerve (Figure 1). It provides the surgeon with desired handling and structural characteristics: pliability of soft tissue, an epineurium to suture the graft in place, and intact endoneurial tubes for the axons to grow through. Available in a variety of sizes, Avance® Nerve Graft allows for a customized repair for gaps from 5 to 70mm in length.

In this case, the patient was a 42-year-old male with a partial median nerve injury from a laceration proximal to the wrist. The injury resulted in loss of sensory and thermal discretion in the long finger and a portion of the ring finger.

Note that the following is only an example of a surgical technique for treatment of a nerve injury. The methods described here may be adapted by the surgeon to fit the specific case being treated.

Surgical Method

Nerve exposure and assessment

1. The injured median nerve segment was exposed, freeing an appropriate amount of the surrounding tissue to visualize the nerve defect.
2. Under an operative microscope, the area of injury was located and two injured fascicles were identified. Internal neurolysis was performed to isolate the injured fascicles while preserving the uninjured fascicles. The ends were resected to healthy, viable nerve both proximally and distally.

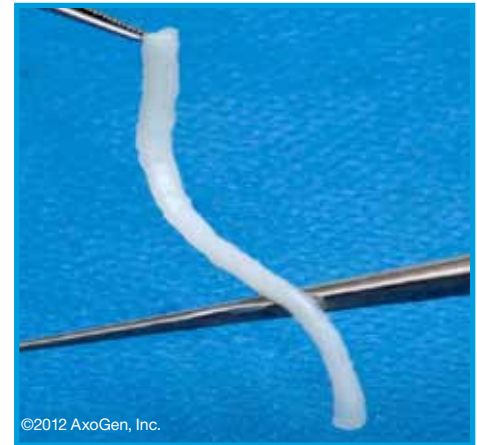


Figure 1: Avance® Nerve Graft, a processed nerve allograft, allows for tensionless repair while providing the desired handling and structural characteristics that are similar to an autograft nerve.

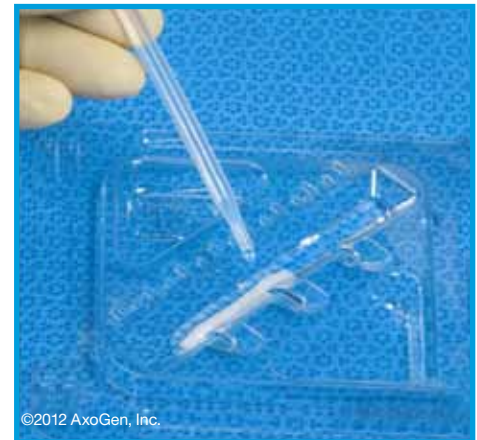

Figure 2: Preparation of Avance® Nerve Graft.

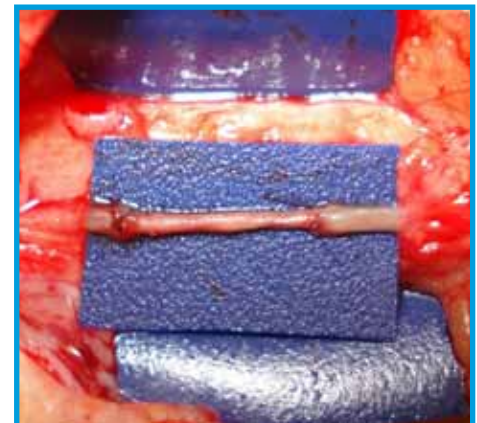


Figure 3: Avance® Nerve Graft used for tensionless repair of median nerve fascicles.

3. The distance between the fascicles was measured to determine if the ends could be directly repaired by primary suturing. It was determined that the defect was too great for a tensionless primary repair and a graft would be required to repair the injured fascicles.
4. An Avance® Nerve Graft of 1-2mm diameter and 30mm length was selected based on the diameter of the transected nerve and length of the gap.

Preparation and Implantation of Avance® Nerve Graft

5. The product was removed from the outer packaging and the inner Tyvek® pouch was passed into the sterile field. In the sterile field, the product tray was removed from the inner Tyvek® pouch.
6. Sterile room temperature Lactated Ringer's solution was added to the thawing reservoir of the product tray and the Avance® Nerve Graft was thawed for 5-10 minutes according to the manufacturer's instructions for use.
7. The 30mm Avance® Nerve Graft was trimmed to yield two 10mm segments for the repair.
8. Each segment was held by the epineurium and carefully placed between the nerve stumps.
9. The epineurium of the processed nerve allograft was sutured to the perineurium of the injured fascicles using three to four interrupted nylon micro-sutures at each coaptation site (Figure 3).

Outcome

Avance® Nerve Graft allowed the ability to match the size of the native fascicles. It handled similar to the native nerve. The 1-2mm diameter graft closely approximated the size of the injured fascicles and was easily sutured in place. The wound healed with no signs of irritation or rejection and the patient displayed continuing progression of Tinell's sign within the first month post repair. Recovery of sensation and two-point discrimination of 8mm was reported by six months. At the six and nine month follow-up visits the patient had demonstrated S3+ recovery of sensation in the affected digits.²

References

1. Yi C and Dahlin LB. Impaired nerve regeneration and Schwann cell activation after repair with tension. *NeuroReport* 2010, 21: 958-962
2. Brooks DN, Weber RV, Chao J, et al. Processed nerve allografts for peripheral nerve reconstruction: A multicenter study of utilization and outcomes in sensory, mixed, and motor nerve reconstructions. *Microsurgery*. Published online 2011 November.

For additional information on



Contact:

AxoGen Customer Care

Phone: 888-AxoGen1 (888-296-4361)

Email: Customercare@AxoGenInc.com

Website: www.axogeninc.com

Unless noted as copyright of AxoGen, Inc., all images are courtesy of Scott M. Wisotsky, MD, a consultant for AxoGen, Inc. Permission for use of information and images are on file at AxoGen, Inc.

©2012 AxoGen, Inc. | Avance® Nerve Graft its logo are trademarks of AxoGen, Inc.

Tyvek® is a registered trademark of E.I. du Pont de Nemours and Company.