

# Clinical Experience with Avance® Nerve Graft for Digital Nerve Reconstruction using AxoGuard® Nerve Connector as a Coaptation Aid

Nirav Gupta, DO, Twin Palm Orthopedics, Ocala, FL

## Introduction

Peripheral nerve injuries affect hundreds of thousands of patients every year in the United States alone. Nerve autografts are currently the gold standard for nerve repair; however use of an autograft nerve is sometimes infeasible and results in donor site morbidity and increased operating room time and costs. As an off-the-shelf alternative to the classic nerve autograft, Avance® Nerve Graft is a decellularized and cleansed extracellular matrix scaffold processed from donated human peripheral nerve. Similar to autografts, Avance® Nerve Graft provides the surgeon with desired handling and structural characteristics: pliability of soft tissue, an epineurium to suture the graft in place, and intact endoneurial tubes for the axons to grow through.

In this case, Avance® Nerve Graft is used for reconstruction of a digital nerve utilizing AxoGuard® Nerve Connectors to reinforce the coaptation sites. The patient was a 66-year-old retiree that sustained a previous laceration to the volar thumb from an open can. Two years after the incident, the patient presented with paresthesia, pain, and Tinel's in the thumb.

Note that the following is only an example of a surgical technique for treatment of a digital nerve injury. The methods described here may be adapted by the surgeon to fit the specific case being treated.

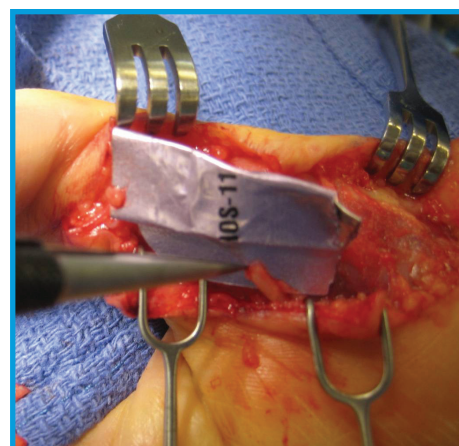
## Surgical Method

### Nerve exposure and assessment

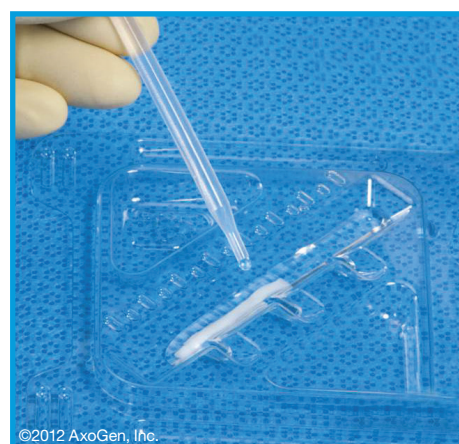1. Procedure was performed with the patient under tourniquet with upper extremity nerve block anesthesia. The previous thumb laceration site was extended distally and proximally about 15 mm. The area was dissected and the radial digital nerve was exposed.
2. External neurolysis revealed a large neuroma at the proximal end of the nerve injury. The neuroma and scar tissue was resected to expose healthy tissue. The proximal and distal nerve stumps were identified, visualized and determined to be appropriate for nerve grafting (Figure 1).
3. Based on the gap between the nerve stumps, an Avance® Nerve Graft 2-3 mm in diameter and 15 mm in length was selected.

### Preparation and Implantation of Avance® Nerve Graft

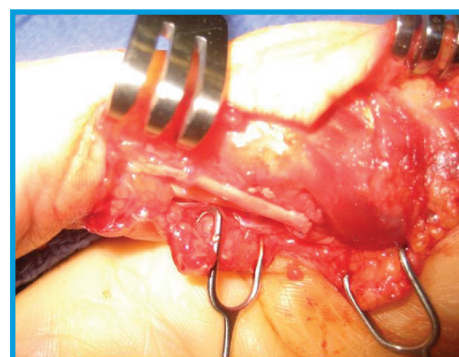
4. The product was removed from the outer packaging and the inner Tyvek® pouch was passed into the sterile field. In the sterile field, the product tray was removed from the inner Tyvek® pouch.



**Figure 1:** Freshened nerve ends after neuroma and scar tissue resection



**Figure 2:** Preparation of Avance® Nerve Graft

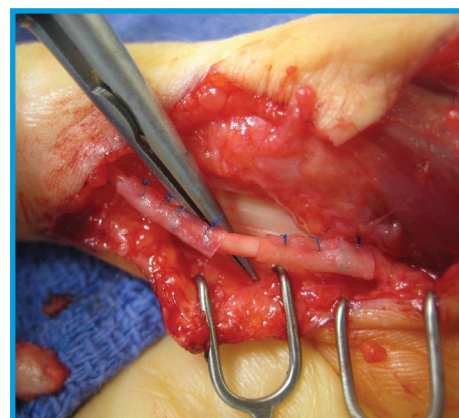


**Figure 3:** Repair of radial digital nerve gap using Avance® Nerve Graft

5. Sterile room temperature saline was added to the reservoir of the product tray, and the allograft was thawed for 10 minutes prior to use (Figure 2).
6. Avance® Nerve Graft was interpositioned into the nerve gap and sutured in place using a 7-0 nylon suture (Figure 3).

### Preparation and Implantation of AxoGuard® Nerve Connectors

7. The nerve connectors were prepared by first peeling open the Tyvek® pouches and passing the trays into the sterile field. The products were hydrated in the pre-molded hydration reservoir of the packaging trays prior to implantation in sterile saline.
8. As the nerve repair was roughly 2 mm in diameter a set of 3 mm AxoGuard® Nerve Connectors were selected to protect the coaptation sites. Each product was cut along the longitudinal axis to create a sheet. AxoGuard® Nerve Connector was then placed around each of the coaptation sites and secured with 7-0 nylon suture, to reinforce and protect the nerve-Avance® Nerve Graft junction. The nerve repair was visualized through each of the nerve connectors to ensure alignment was maintained and the nerve was not impinged (Figure 4).
9. Upon completion of the procedure the tourniquet was released, hemostasis was achieved, the wound was thoroughly irrigated and the incision was closed.



**Figure 4:** AxoGuard® Nerve Connector used as a coaptation aid over repair sites

## Outcome

Avance® Nerve Graft allowed for reconstruction of the nerve discontinuity. Being of human tissue origin, the processed nerve allograft handled similarly to the native nerve and was easily incorporated into the repair. The 2-3 mm diameter graft closely approximated the size of the injured nerve and was easily sutured into place. AxoGuard® Nerve Connectors have a low profile and when hydrated were easily conformable to the nerve. The connectors were sutured over the nerve-nerve graft coaptation points to help secure and reinforce the repair. They also serve as a barrier to scar tissue infiltration and create a protected environment in which nerve can heal. Following the repair, there were no signs of complications, impaired wound healing or signs of irritation or infection. At one month post-op the patient is progressing well with complete resolution of pain and returning sensation to the thumb.

For additional information on



Contact:

**AxoGen Customer Service**  
**Phone: 888-AxoGen1 (888-296-4361)**  
**Email: [Customerservice@AxoGenInc.com](mailto:Customerservice@AxoGenInc.com)**  
**Website: [www.axogeninc.com](http://www.axogeninc.com)**

Unless noted as copyright of AxoGen, Inc., all images are courtesy of Nirav Gupta, DO, a consultant for AxoGen, Inc. Permission for use of information and images are on file at AxoGen, Inc.

AxoGen, Inc., Avance® Nerve Graft and AxoGuard® Nerve Connector and their logos are trademarks of AxoGen, Inc. Tyvek® is a registered trademark of E.I. du Pont de Nemours and Company.